



PATIENT

Wilko Raushi

PRESENTING CLINICAL SIGNS

History: ProBNP severely increased: 764. T4 borderline.

SPECIES

Feline

BREED

DSH

SEX

Male Neutered

ECHOCARDIOGRAM FINDINGS

2D, m-mode, color flow and doppler imaging is available. The left ventricular wall is mildly hypertrophied. There is a diffusely hyperechoic endocardium consistent with fibrosis and ventricular remodeling. Mild papillary muscle remodeling. The right ventricle is subjectively normal in size and morphology. There is borderline left atrial enlargement present. No right atrial enlargement present. Normal RVOT velocity. Mild systolic anterior motion (SAM) of the mitral valve present, with an elevated LVOT velocity (not captured on Spectral). There is mild eccentric mitral regurgitation present secondary to SAM. Trace TR. No other significant valvular regurgitation is present. There is no pericardial effusion noted. No pleural effusion appreciated. No obvious cardiac tumors.

CARDIAC CHART

AGE

12 years

WEIGHT

11.25lbs

INTERPRETED BY

Maggie Machen Lamy,
DVM, DACVIM
(Cardiology)

IMAGING PERFORMED BY

Sands Hill Mobile
Veterinary Ultrasound

HOSPITAL NAME

Surf City Animal
Hospital

REFERRING VET

Dr. Wick

INVOICE

24820

DATE

6/16/22

| FELINE CARDIAC PARAMETERS | BODY WEIGHT (kg) | HR (BPM) | IVSd (cm) (Moise, Pipers) | LVIDd (cm) (Moise, Pipers) | LWVd (cm) (Moise, Pipers) | FS (%) | EF (%) |
|---------------------------|------------------|---------------------------------|--|----------------------------|---------------------------|----------------|-------------|
| NORMAL PARAMETER | ----- | 150-240 | 0.35-0.55 | <2 (mean 1.5) | 3.5-0.55 | 35-67 | 80-100 |
| PATIENT | 5.1 | 188 | 0.64 | 1.36 | 0.64 | 52 | 90 |
| FELINE CARDIAC PARAMETERS | LA/AO (Boon) | LA/AO HEART BASE (Swe) (Abbott) | LA 2D short axis Base view (cm) (Abbott) | | LVOT VEL (m/s) | RVOT VEL (m/s) | E max (m/s) |
| NORMAL | <1.5 | <1.3 | <1.2 | | <1.6 | <1.3 | <0.9 |
| PATIENT | 1.5 | 1.4 | 1.38 | | 1.3 | 0.8 | NM |

**Note: All measurements based upon multi-modal images and methods. An average value is reported.*
Adapted from June Boon, Veterinary Echocardiography, 1998
Abbott J & MacLean H JVIM 2006;20: 111-119, Moise et al. Am J Vet Res 47:1476, 1986. Pipers et al. Am J Vet Res 40:882, 1979.

INTERPRETATION OF THE FINDINGS & FURTHER RECOMMENDATIONS

The diagnosis is hypertrophic obstructive cardiomyopathy (HOCM). This indicates LV thickening (mild in this case) with a dynamic LVOT obstruction (SAM) and secondary mitral regurgitation as the cause of the heart murmur. The hypertrophy and obstruction are both mild. There is minimal left atrial enlargement present, indicating the risk of spontaneous CHF and/or a thrombotic event is currently low. No additional issues are identified.

While no medications have been shown to definitively alter long term outcome at this stage of disease, atenolol is often initiated to decrease the outflow obstruction. If the patient is easily medicated, it is reasonable to initiate at this time as below. If there is difficulty medicating at home, an alternative approach would be closely monitoring for progression in the next 6-12 months. Discussion with the owner is advised. No additional medications are indicated prior to significant atrial dilation.

Monitor at home for any respiratory signs or blood clot events (neurologic change, paralysis, etc.). Anesthetic risk is considered mild, however judicious IV fluid rates are advised to avoid fluid



PATIENT

Wilko Raushi

overload. Additionally, drugs that stimulate heart rate should be avoided unless clinically necessary (ketamine, glycopyrrolate, atropine).

SPECIES

Feline

PLAN

If elected, administer titrating dose of atenolol: 25mg tablets; Give ¼ tab once daily. Recheck heart rate in 1-2 weeks with target stressed rate of 140-160bpm 12-24 hours post-administration. Increase as needed until target reached. Screening blood pressure and T4 are recommended every 6 months.

BREED

DSH

Recommend recheck echocardiogram in 6 months to assess for progression, sooner if clinical issues arise.

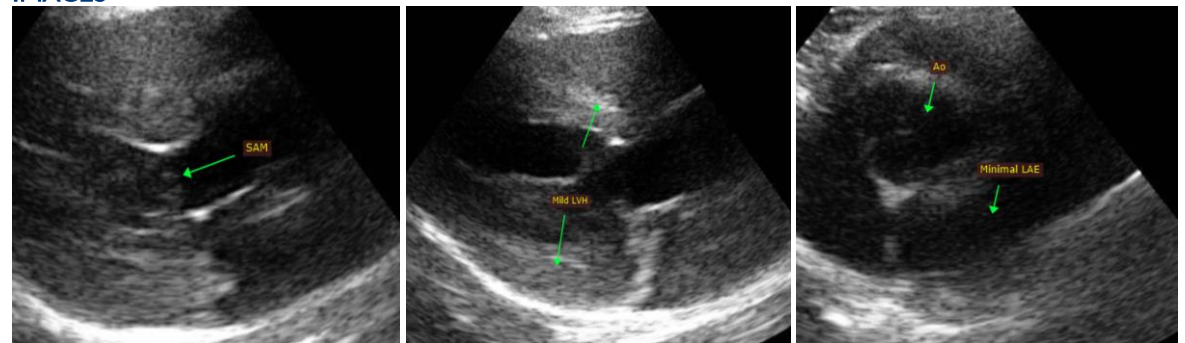
SEX

Male Neutered

IMAGES

AGE

12 years



WEIGHT

11.25lbs

INTERPRETED BY

Maggie Machen Lamy,
DVM, DACVIM
(Cardiology)

The information and recommendations provided are based on the images presented by the referring veterinarian. No evaluation can be communicated regarding pathology that was not visible in the image/video clips provided.

IMAGING PERFORMED BY

Sands Hill Mobile
Veterinary Ultrasound

Thank you for this referral. This report was generated using transcription software, and minor dictation errors may be present. If the clinical or image interpretation does not parallel your findings or if I can be of any further assistance, please contact me.

Maggie Machen Lamy, DVM
Diplomate of the American College of Veterinary Internal Medicine (Cardiology)
info@sonopath.com

HOSPITAL NAME

Surf City Animal
Hospital

REFERRING VET

Dr. Wick

INVOICE

24820

DATE

6/16/22